ASHERMAN'S SYNDROME

What the patient has to say

by Deborah Ostrovsky Osmond

It's impossible to hear any hint of bitterness in Aimée's voice. The 32-year-old public relations specialist sounds positively upbeat. Her cheerfulness makes it hard to believe that, for the past two years, her life has been consumed by a fertility struggle caused by a condition called Asherman's Syndrome.

Aimée's desire to start a family has taken her on an emotional, and physically painful, journey across the continent, searching for answers and surgical treatments from some of North America's top fertility specialists.

She's accumulated a lot of air miles, but the exhaustion is taking its toll. "It's been really hard, and I have a few new gray hairs to prove it," she says with a tinge of anguish as she talks to me on the phone.

Aimée didn't always have trouble conceiving. Young and healthy, she became pregnant naturally. In June 2008, she and her husband Steven were "over the moon with joy" to discover that they were expecting their first baby. Unfortunately, their elation ended in sorrow with a miscarriage at eleven weeks.

Although common, a first-trimester miscarriage feels like a tragedy. But the "real nightmare", as Aimée calls it, began with a minor surgery called a dilation and curettage (D&C) to remove contents of the miscarriage from her womb. After her D&C, everything appeared to be normal. Then, a month after surgery, the troubles started. Little did she know that the D&C would unleash a series of health complications leading to Asherman's Syndrome, a condition caused by intrauterine adhesions, bands of scar tissue called synechiae in the uterus.

Untreated, Asherman's can have severe consequences. Aside from scarring the uterine cavity, it can cause intense pelvic pain, cramping, endometriosis and infertility. Caught early, the situation is more hopeful. Many women who undergo treatment for mild to moderate scarring will go on to deliver a healthy baby.
But Aimée knows about the severe

consequences. With over 75 percent of the endometrial lining of her womb filled with scars, she may never be able to have a much longed-for child.

Asherman's Syndrome is frequently called a "rare" condition. Yet medical researchers are finding that the incidence of scarring after one D&C can be as high as 16%.[1] Others are concerned that the syndrome is underdiagnosed, and may even be on the rise.

"Unless it is recognized by gynecologists as a not uncommon entity," wrote British husband and wife medical team Kenneth and Roxana Chapman two decades ago in the *Journal of the Royal Society of Medicine*, "it will continue to be missed."[2]

These days, everyone agrees that early diagnosis and treatment for Asherman's are key to preventing infertility. But the syndrome is still considered rare enough that many women, including Aimée until her diagnosis, have never heard of it. With Asherman's so far off the radar for doctors and patients, treatment is often delayed, and prevention is difficult when the prevalence of risk factors are underestimated. This is why Aimée is sharing her story, urging women to learn more about Asherman's symptoms as well as speak to their doctor if they suspect something is wrong.

The first observations about intrauterine adhesions (IUA) were made in Germany in 1894. Dr. Heinrich Fritsch treated a woman whose periods suddenly stopped after he removed bits of retained placenta from her womb following childbirth. Over 50 years later, Israeli gynecologist Joseph G. Asherman published a series of groundbreaking articles about uterine scarring. He showed that trauma to the lining of the uterus, the endometrium, could be caused by curettage. This procedure uses a small instrument, a curette, to scrape retained products of conception (RPOC) from the womb following a pregnancy or miscarriage. The syndrome has been named after Dr. Asherman ever since. Hallmark signs of Asherman's are the sudden onset of menstrual irregularities after surgery. Women may notice that the flow of their period becomes lighter, or that it stops altogether (called amenorrhea). Despite missing periods, many women continue having painful menstrual cramps.

Nowadays, there is a growing list of risk factors for scarring, including postpartum infection and pelvic inflammatory disease (PID). Radiation treatment of the pelvis, as well as uterine surgery for the removal of fibroids (myomectomy) or hysteroscopy can also pose a risk. Although rarely, some women may even develop scarring without a specific cause.

But the greatest number of reported cases are from using the curette to scrape or suction the contents of a recently pregnant uterus. This is when the womb is most vulnerable to trauma: in the days or weeks following birth, an elective abortion, or as in Aimée's case, after a miscarriage.

> The "real nightmare" began with a minor surgery called a dilation and curettage (D&C) to remove contents of the miscarriage from her womb.

Researchers are optimistic about preventative measures for reducing the risk of adhesions after a D&C. These include performing curettages more gently, using ultrasound to guide the surgery, and closer monitoring for complications after birth to reduce uterine trauma.

Aimée's Asherman's journey started with a D&C. She knew that her miscarriage was one of nature's sad events, something that could be neither prevented nor cured. She found herself in a waiting game, nervous about the unpredictable timing of miscarrying naturally. So she made a quick decision.

It was six o'clock at night when she was wheeled into the operating room at a hospital in downtown Toronto.

Shelley Gibbs BSc (Hon), ND
Doctor of Naturopathic Medicine

Duke Street Centre for Change and Wellness
111 Duke Street East, Suite A
Kitchener ON, N2H 1A4
Tel. 519-342-0034 Fax. 519-342-0245
shelley@shelleygibbsnd.ca

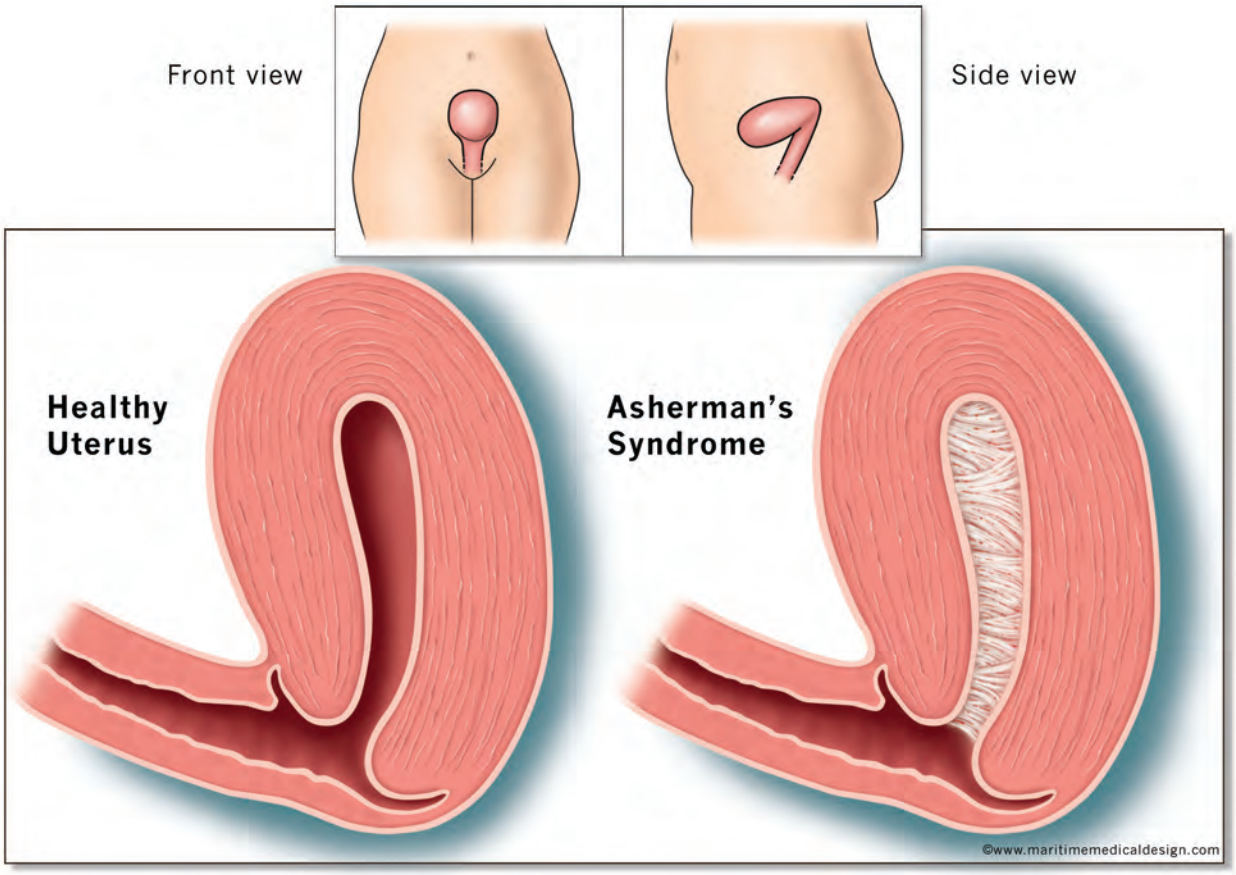

The womb is most vulnerable to trauma in the days or weeks following birth, an elective abortion, or as in Aimée's case, after a miscarriage.

"I didn't think twice about having a D&C. So many women have them," she recalls, adding that she had never been warned about the severity of the risks of this routine procedure. Twenty minutes later, she was out of the operating room. She left the hospital the same night, prepared for the moderate bleeding she had been told by her doctor to expect over the next few days.

At first, her recovery was uneventful. But a month and half later, her period hadn't returned. Then it finally started. This time, it didn't stop.The bleeding alternated with intense cramping. Worried, Aimée went to her family doctor, who reassured her that menstrual irregularities following a miscarriage are normal. After a few more months of bleeding and discomfort, Aimée wanted answers. "I started to panic," she recalls. On yet another sleepless November night, doubled over with cramps, she turned to her husband sleeping beside her.

"I can't take this anymore," she said to Steven. "We're going to emergency."

A gamut of tests at the hospital revealed that Aimée probably had an arteriovenous malformation (AVM) in her uterus. The ob-gyn on call told her that there was nothing they could do except continue monitoring the small, tangled ball of vessels making her bleed. Aimée went home, amazed that the only option doctors gave her was to endure the chronic hemorrhaging endangering her health.

So she looked for answers. In February 2009, she found herself lying on an examination table in a new specialist's office, waiting for the results of her first sonohysterogram (SHG), a test using ultrasound while saline solution is injected into the uterus to detect abnormalities.

The doctor's news shocked her. "My specialist took one look at my ultrasound and told me that the

bleeding was probably caused by contents of the pregnancy left over from my miscarriage—six months earlier," Aimée says.

She underwent a hysteroscopy to remove the remainder of her miscarriage.

With a sigh of relief, Aimée thought her troubles were finally over. A month later, she felt the mild cramps that usually preceded her period. But there was no blood. So she was prescribed medication to induce menstruation. Then, still no bleeding. Two months later, her worries started again.

"I was getting bloated. I felt like I was getting my period, but nothing was happening," she says, recalling the panic she felt.

During the weeks waiting for a follow-up appointment with her specialist, she looked up her symptoms online. Her research led her to an Asherman's Syndrome international support group (www.ashermans.org) founded by Poly Spyrou from Cyprus, who also lives with this condition.

One by one, Aimée matched her own symptoms with the description of Asherman's online. Pain around the time of menstruation, but no blood. Previous uterine surgery. A D&C for missed miscarriage, followed by hemorrhaging. Surgery for retained contents of pregnancy. Infertility.

"I think I have this," she said aloud, nervously scrolling through reams of medical information on her computer screen.

The women she corresponded with on the site encouraged her to mention Asherman's to her doctor. She did. And in May—almost a year after first becoming pregnant—she was officially diagnosed with Asherman's Syndrome.

Despite her sadness, Aimée jumped into action. After almost a year of discomfort, she took an unpaid leave from work. Now her full-time job was to take care of herself.

On the Asherman's website, she found out about a highly regarded specialist in Los Angeles, California, who specializes in treating complex cases of intrauterine adhesions, including those of other Canadian women. Faced with a four-month wait for surgery in Canada, she hopped on a plane to the US, where she could be treated almost immediately.

The US doctor's news was not good. Her Asherman's was severe. But she has undergone two successful hysteroscopy surgeries using microscissors to gently cut away the scars. After hysteroscopy, she was given treatment with hormone therapy to encourage her endometrial lining to grow. A small balloon catheter was placed in her uterus following hysteroscopy so that the scars couldn't grow back, or fuse the walls of her womb together.

At home in Toronto, she is followed by a fertility specialist who collaborates with her doctor in the US. Her periods have returned, but her reproductive future is uncertain because of the damage from scarring.

Aimée is not alone on her journey. She's in touch with other women who have Asherman's. Their stories may all be unique—some have had D&Cs after a miscarriage, and others to remove retained placenta after giving birth. But they all possess one common feature: a long, unwieldy search for diagnosis after noticing menstrual changes.

Is enough being done to ensure that Asherman's can be prevented, or caught early enough so women who develop scarring can have optimal treatment? For Aimée, this question might come a little late, although with treatment, there is still hope for her future.

About the author

Deborah Ostrovsky Osmond is a freelance writer and editor living in Montreal with an interest in women's reproductive health.

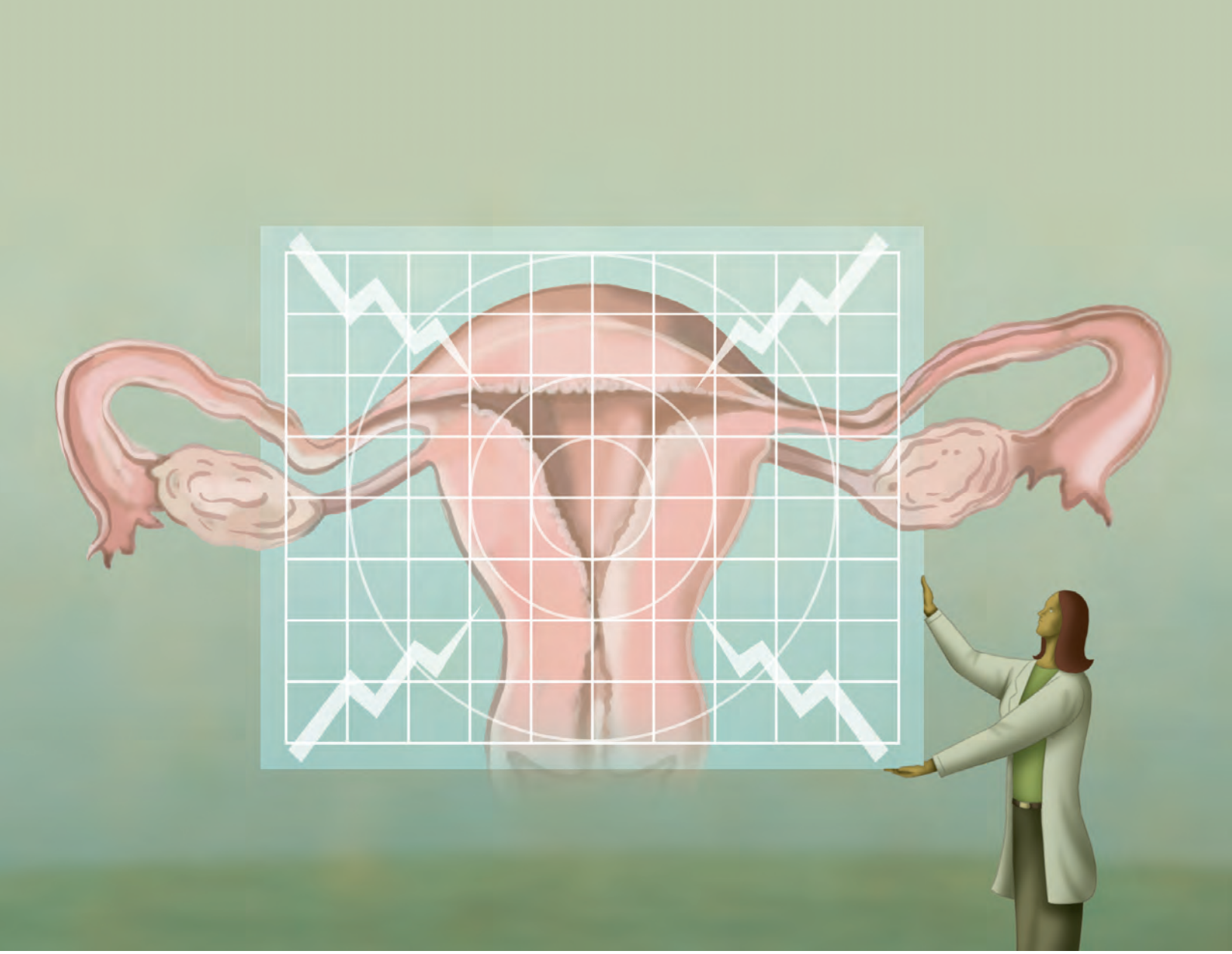

ASHERMAN'S SYNDROME

The Doctor's Report

by Sony Sierra, MD, MSc, FRCSC

Infertility affects many couples in Canada, with estimates of up to 15% of the reproductive-aged population. While infertility has many etiologies (causes), anatomical or structural factors account for approximately 15-20% of cases. Asherman's Syndrome, also known as intrauterine adhesions (IUA), is recognized as an uncommon but causative factor in recurrent early pregnancy loss and infertility.

Asherman's Syndrome was first reported in 1894 and the term is used to describe partial or complete obliteration of the uterine cavity by adhesions, leading to menstrual abnormalities, infertility or recurrent pregnancy loss. It has been reported in about 1.5% of all women suffering from infertility, and in up to 39% of women with recurrent pregnancy loss.

What is it?

The adhesions or scar tissue characteristic of Asherman's Syndrome lead to the loss of normal endometrial tissue (or uterine lining). The extent of this syndrome can vary from very minimal scar tissue to complete obliteration or loss of the normal uterine cavity.

How does it happen?

The major cause of IUA formation is trauma to the uterine lining. This can occur as a side effect of surgery or curettage of the uterus, for example from a dilation and curettage (D&C) procedure for management of a miscarriage or retained products after delivery. In fact, the uterus is at highest risk of scar formation in the first four weeks after delivery.

Asherman's Syndrome can also result from a severe pelvic infection contracted during surgery or post-operatively. Very rare causes of Asherman's Syndrome include tuberculosis or schistosomiasis; these are unlikely to occur in North America, however.

How would I know if I had IUA?

Typical symptoms of this syndrome include:

- Fewer, infrequent, irregular periods
- Loss of periods
- Cyclical pelvic pain
- Infertility
- Recurrent early pregnancy loss
- History of sharp D&C for miscarriage or for retained placenta after delivery

How is the diagnosis confirmed?

A standard investigation of infertility and recurrent miscarriage includes a structural assessment of the uterus. A pelvic ultrasound provides useful information about the exterior structure, size, and overall shape of the uterus. It detects the presence of fibroids in the muscle wall or on the exterior (serosal) surface of the uterus. Ultrasound is also an excellent way to evaluate the size of the ovaries and the presence of important follicles and/or cysts. Information about the uterine lining or endometrium requires more specialized imaging.

The best way, or "gold standard", of investigating the endometrium is to look directly at the lining with a hysteroscope (Soures et al, 2000). This is a surgical procedure known as diagnostic hysteroscopy and it can usually be performed as an office procedure without medication. A physiologically balanced fluid is injected into the uterus while a small scope attached to a camera is inserted through the cervix into the uterine cavity. This allows the surgeon to obtain a direct view of the lining and determine the nature and extent of the scarring, or IUA.

> Although uncommon, Asherman's Syndrome has been reported in up to 39% of women with recurrent pregnancy loss.

Sonohysterography, or obtaining a sonohysterogram, is also used to diagnose IUA or Asherman's Syndrome. This is an ultrasound-based procedure that involves taking images of the uterine lining while saline is slowly injected into the uterine cavity. When this is combi-

ned with three-dimensional sonohysterography, it can very accurately diagnose IUA, as well as measure the size of the entire uterine cavity.

> The major cause of intrauterine adhesions formation is trauma to the uterine lining. This can occur as a side effect of surgery or curettage of the uterus.

Is there a way to treat IUA?

Operative hysteroscopy is the treatment of choice for IUA. The technique is similar to a diagnostic hysteroscopy. While images are being taken, a skilled reproductive surgeon uses hysteroscopic scissors, cautery or laser to sharply cut or dissect the adhesions.

In the hands of a skilled surgeon, all of these techniques result in similar outcomes (Zikopoulos et al, 2004). The anatomy of a normal uterine cavity is usually achieved after one hysteroscopic procedure; however, this doesn't always guarantee that the lining will heal normally, nor does it guarantee a pregnancy or live birth.

Once the adhesions are cut, the next step in treatment involves prevention of future adhesions, or the reformation of IUA. This is a particular risk if the adhesions were extensive and there is very little normal endometrial lining to regenerate and line the newly formed cavity.

Post-operative adhesion formation occurs in almost 50% of severe cases and 22% of moderate cases (Valle & Sciarra, 1988). The science behind preventing these adhesions is not clear on which is the better method, but your doctor can choose between hormonal therapies, mechanical methods or both in an attempt to prevent future scarring.

If hormonal therapy is used, the objective is to stimulate endometrial development and healing after adhesions are cut. There are several options for treatment, but a standard approach often involves twice-daily doses of oral estrogens for anywhere from 2 weeks to 30 days, with or without the addition of progesterone or a synthetic progestin during the last 10-14 days of estrogen therapy.

Mechanical methods include the insertion of an IUD for about 30 days (Zikopoulous et al, 2004) or the insertion of a Foley catheter (or intrauterine balloon) for 1-2 weeks (Orhue et al, 2003).

What are the success rates after treatment?

The overall pregnancy rate after lysis (removal) of adhesions is approximately 60%, with a live birth rate of 40%. These figures come from a comprehensive review of 800 women with Asherman's Syndrome who were treated with hysteroscopic surgery (Sieglar & Valle, 1988). In women with recurrent pregnancy loss, after surgery the rates of early loss decrease from 86% to 43% (Goldenberg et al, 1995).

When presented with infertility, it is always important to evaluate all possible causes, even in the case of known intrauterine adhesions. While most women conceive after surgery for IUA, there are some that continue to face infertility. In one study, almost 60% of women in a group who did not conceive after treatment of IUA actually had other causes for infertility (Roge et al, 1996).

Intrauterine adhesions can be a reason for infertility, especially in women who have undergone multiple uterine surgeries or uterine procedures in the postpartum period. Proper diagnosis and management in the hands of skilled reproductive surgeons can result in the return of normal menstrual and reproductive function.

For more information, or for support and other resources, visit: www.ashermans.org



About the author

Dr. Sierra practices Gynecologic Reproductive Endocrinology & Infertility in Toronto, where she is co-founder of First Steps Fertility Inc. She graduated from Medicine and a residency in Obstetrics & Gynecology at the University of Toronto. She then specialized in Infertility and Recurrent Miscarriage through further training in a Royal College of Canada accredited fellowship program at the University of British Columbia and the University of Chicago. After completion, she was appointed Assistant Professor, Clinician Investigator in the Department of Obstetrics & Gynecology at the University of Toronto. She is currently enrolling patients with a history of recurrent pregnancy loss and recurrent implantation failure after IVF in a study to document the expression of genes in the endometrial lining.